

Amplitude-integrated electroencephalography for neonatal seizure detection. An electrophysiological point of view

Electroencefalograma integrado por amplitud para la detección de convulsiones neonatales. Un punto de vista electrofisiológico

Sebastián Gacio^{1,2}

ABSTRACT

Seizures in the newborn are associated with high morbidity and mortality, making their detection and treatment critical. Seizure activity in neonates is often clinically obscured, such that detection of seizures is particularly challenging. Amplitude-integrated EEG is a technique for simplified EEG monitoring that has found an increasing clinical application in neonatal intensive care. Its main value lies in the relative simplicity of interpretation, allowing nonspecialist members of the care team to engage in real-time detection of electrographic seizures. Nevertheless, to avoid misdiagnosing rhythmic artifacts as seizures, it is necessary to recognize the electrophysiological ictal pattern in the conventional EEG trace available in current devices. The aim of this paper is to discuss the electrophysiological basis of the differentiation of epileptic seizures and extracranial artifacts to avoid misdiagnosis with amplitude-integrated EEG devices.

Keywords: Electroencephalography; seizures; neonatal seizures.

RESUMO

Las convulsiones neonatales están asociadas a una alta morbi-mortalidad por lo que su correcto diagnóstico y tratamiento es fundamental. Las convulsiones en los recién nacidos son frecuentemente subclínicas lo que hace que su detección sea dificultosa. La electroencefalografía integrada por amplitud es una técnica de monitoreo electroencefalográfico simplificado que ha encontrado una creciente aplicación clínica en las unidades de terapia intensiva neonatales. Su principal ventaja es la relativa simplicidad de su interpretación lo que permite a personal no especializado del equipo neonatal diagnosticar convulsiones electrográficas en tiempo real. Sin embargo, para evitar diagnosticar erróneamente artefactos rítmicos como crisis epilépticas es necesario reconocer los patrones electrofisiológicos ictales en el EEG convencional disponible en los dispositivos actuales. El objetivo de este artículo es describir las bases electrofisiológicas para la diferenciación de convulsiones neonatales y artefactos extracraneales para evitar errores diagnósticos con el uso de EEG integrado por amplitud.

Palabras-clave: Electroencefalografía; convulsiones, convulsiones neonatales.

The neonatal period has the greatest incidence of seizures in life, with 1.8-3.5 per 1,000 live births¹. Seizures in the newborn are associated with high morbidity and mortality, which make their detection and treatment essential^{2,3}.

Seizure activity in neonates is often difficult to observe, making the detection of seizures particularly challenging. Clinical observation alone can lead to underdiagnosis of neonatal seizures, as nearly 80% of seizures can be occult⁴. It is for these reasons that effective methods for seizure detection are of fundamental importance in neonatal care.

Electrophysiological brain activity, as measured by electroencephalography (EEG), is well established as a tool for providing information regarding the functional and metabolic state of the brain and the occurrence of epileptic seizure episodes⁵. In neonatal care, EEG has been used extensively for estimation of the degree of cerebral maturation in preterm infants and for detection of abnormal patterns indicating focal and global cerebral lesions^{6,7,8}. In the neonatal setting, as well as in intensive care in general, the EEG is most often recorded for a patient intermittently, at

¹ Hospital de Niños Ricardo Gutiérrez, División de Neurología, Ciudad Autónoma de Buenos Aires, Argentina.

² Hospital Juan A. Fernández, División de Neonatología, Ciudad Autónoma de Buenos Aires, Argentina.

Sebastián Gacio  <https://orcid.org/0000-0002-0017-0208>

Correspondence: Sebastián Gacio; División de Neurología, Hospital de Niños R. Gutiérrez. Gallo 1330 (C1425EFD), Ciudad Autónoma de Buenos Aires, Argentina. E-mail: neurogacio@gmail.com

Conflict of interest: There is no conflict of interest to declare

Received 28 January 2018; Received in final form 03 October 2018; Accepted 15 October 2018.

best serially and, on rare occasions only, continuously^{9,10}. A limiting disadvantage with intermittent conventional EEG during neonatal care is the difficulty in discriminating emerging trends of development of the electrocerebral activity over hours and days. This interpretation, if possible at all, requires specialized skills not usually available in the neonatal intensive care unit (NICU)⁵. Thus, the main disadvantage with intermittent conventional EEG during neonatal care is the inability to diagnose seizures when they occur.

Amplitude-integrated EEG (aEEG) is a technique for simplified EEG monitoring that has found an increasing clinical application in neonatal intensive care. Its main value lies in allowing real-time detection of electrographic seizures, providing the opportunity for treatment at the time they occur, and not requiring specialized staff for their interpretation.

Several studies have evaluated the sensitivity and specificity of aEEG for the diagnosis of neonatal seizures with variable results.¹¹⁻²³ However, these studies have not addressed the importance of electrophysiological interpretation of aEEG findings.

One advantage of aEEG over conventional EEG is that the former does not require specialized staff for their interpretation. Nevertheless, for its correct interpretation, and to avoid misdiagnosing rhythmic artifacts as seizures, it is necessary for members of the care team to recognize the electrophysiological ictal patterns in the conventional EEG trace available in current devices. Many false positives in the aEEG pattern can be easily recognized when reviewing the raw trace²³.

Despite the importance of the recognition of these patterns during the use of aEEG, electrophysiological diagnosis of seizures is seldom emphasized. Previous papers have not explored the electrophysiological basis of seizure detection using current aEEG devices. The aim of this paper is to discuss the electrophysiological basis of the differentiation of epileptic seizures and extracranial artifacts to avoid misdiagnosis with aEEG devices.

ELECTROCLINICAL ASPECTS OF SEIZURES IN THE NEONATAL PERIOD

The electrographic and clinical characteristics of seizures in the neonate are unique compared with older children and adults²⁴. In the neonate, electrographic seizure patterns vary widely, electrical seizure activity does not accompany all behaviors considered to be seizures, and electrographic seizures frequently occur without evident clinical seizures²⁵⁻²⁷.

From the perspective of the neonatal EEG, neonatal seizures can be classified according to the temporal relationship between the electrical event and the clinical event:

electroclinical seizures (a clinical seizure with ictal electrographic correlation), clinical-only seizures (clinical seizure without concurrent electrographic correlate), and electrographic seizures (ictal electrographic abnormalities without concurrent clinical seizures)^{28,29}.

Electroclinical seizures are characterized by a temporal overlap between clinical seizures and electrical seizure activity on the EEG. In many instances, the electrical seizure and clinical events are closely associated, with the onset and termination of both events coinciding²⁵.

Focal clonic, focal tonic, and some myoclonic seizures and spasms are associated with electrical seizure activity. These are epileptic in origin^{30,31}.

Electrographic seizures (electrical seizure activity with no clinical accompaniment) are very frequent in the newborn. Typically, no behavioral changes are associated with seizure discharges^{4,32}. One frequent cause of electrographic seizures is the use of antiepileptic drugs²⁸. The antiepileptic drugs may suppress the clinical component of the electroclinical seizure but not the electrical component, thus the clinical seizure may be controlled but electrical seizure activity may persist. However, electrographic seizures are frequent in the neonatal period even without antiepileptic treatment. These seizures will be undiagnosed without the use of EEG monitoring³³.

Some types of clinical seizures have no specific relation to electrical seizure activity³⁴. Those that occur in the absence of any electrical seizure activity include generalized tonic, motor automatisms, and some myoclonic seizures. These clinical events are initiated and elaborated by nonepileptic mechanisms³⁵. When these nonepileptic clinical episodes are erroneously diagnosed as epileptic seizures, there is a risk of unnecessarily treating newborns with antiepileptic drugs that are not required.

AMPLITUDE-INTEGRATED ELECTROENCEPHALOGRAPHY

General information

Amplitude-integrated EEG was first designed by Maynard as the cerebral function monitor in the 1960s and originally applied in adult intensive care by Prior³⁶. The method was first used in newborn babies in the late 1970s and early 1980s³⁷.

This method is based on a time-compressed (usually 6 cm/hour) semi-logarithmic (linear 0–10 mV, logarithmic 10–100 mV) display of the peak-to-peak amplitude values of EEG passed through an asymmetrical bandpass filter that strongly enhances higher over lower frequencies, with suppression of activity below 2 Hz and above 15 Hz. This approach minimizes artifacts from sources such as sweating, movement, muscle activity, and interference but may obscure some seizures. The current devices consist mainly of

two independent channels of aEEG and their corresponding two-channel conventional EEGs available on the screen for simultaneous viewing.

The EEG trace of the neonate is characterized by intermittent bursts of high amplitude, intermixed with lower amplitude continuous activity. The bandwidth of the aEEG curve reflects variations in minimum and maximum EEG amplitude. The semi-logarithmic display enhances identification of changes in the low voltage range and avoids overloading the display at high amplitudes⁵.

The aEEG technique extracts the cerebral activity and transforms it into five basal activity patterns (interictal patterns) and one ictal (seizures) pattern. The background pattern is defined as continuous (normal pattern with sleep-wake cycle), discontinuous (moderate abnormal in full-term newborns), burst suppression (pathologic or drug induced), low voltage and flat/isoelectric (Figure 1 A-D). This system is applicable to newborns of all ages and diagnoses³⁸. An ictal pattern (seizures) is usually seen as an abrupt increase of maximal and minimal aEEG amplitude, seldom only the minimal amplitude, often followed by a transient postictal amplitude depression (Figure 1 E)⁵. The aEEG devices show the conventional EEG trace simultaneously with the aEEG trace to confirm the aEEG findings.

The discovery that information displayed by the aEEG paradigm can predict outcome after perinatal asphyxia has attracted medical attention and been the subject of numerous publications each year. Currently, aEEG is being used as an inclusion criterion in studies of therapeutic hypothermia³⁹⁻⁴⁵. However, an often-ignored value of aEEG is its utility for real-time detection of seizures.

There is controversy regarding the sensitivity and specificity of aEEG for electrographic detection of seizures, especially in comparison with conventional EEG¹¹⁻²³. But even with less sensitivity and specificity, the aEEG has numerous advantages: it allows for continuous monitoring over long periods of time; the simplicity of its interpretation does not require extensive training; and its use permits immediate detection and treatment of seizures.

Although aEEG is easily interpreted by personnel who have not trained in electrophysiology, familiarity with some relatively simple electrophysiological characteristics is necessary for the correct diagnosis of seizures.

The electrophysiological diagnosis of epileptic seizures and its differentiation with extracranial artifacts

It is a challenge for all involved in neonatal care to accurately diagnose neonatal epileptic seizures, as nearly 80% of them are subclinical^{46,47}. The use of EEG monitoring permits detection of seizures, but there are many artifacts visible in both EEG and aEEG traces that can be misdiagnosed as seizures. Differentiating a nonepileptic rhythmic pattern from a seizure in the aEEG trace can also be

challenging because both have a similar appearance: a sudden rise in minimal and maximal amplitude. To differentiate between them, it is necessary to review the conventional EEG tracing and to know the electrophysiological characteristics of epileptic seizures.

The hallmark of an electrographic seizure, visible in conventional EEG, is the sudden appearance of repetitive discharge events consisting of a definite beginning, middle and end, that evolve in frequency, morphological appearance and amplitude (Figure 2)¹⁰.

This pattern should be always reviewed in the conventional EEG trace available in current devices (Figure 3). Infrequently, the ictal pattern does not include evolution and instead manifests as regular repetitive spikes or regular rhythmic slowing.

The ictal pattern recorded from the scalp at the start of the seizure can take different forms. The predominant frequency in a given seizure can be in the delta (0–3 Hz), theta (4–7 Hz), alpha (8–13 Hz) or beta (14–30 Hz) frequencies, or be a mixture of these, with different morphology: spikes, sharp waves, slow waves, spike and waves, electrodecremental activity (a diffuse flattening of brain rhythms), then evolving in frequency, amplitude and/or morphology^{30,40,48-50}. The voltages of the activity may also vary, from extremely low (usually when faster frequencies are present) to very high (commonly seen when slow frequencies are present) and evolve within the seizure³².

The evolving pattern helps us to distinguish electrographic seizures from the wide range of nonepileptic paroxysmal behavior that may occur in healthy or sick infants, especially from extracerebral artifacts produced by the neonate or neonatal care and procedures⁵¹. Some of these extracerebral artifacts are rhythmic, so they may be confused with ictal activity. However, these artifacts are typically monomorphic and do not evolve in frequency, morphological appearance or amplitude (Figure 4).

Other characteristics that help to differentiate between a seizure and a rhythmic artifact are the electric field and the spread of the seizure to other areas of the brain, both visible only in the case of epileptic seizures (Figure 1). The cerebral activity should have an electric field: it should be reflected in physically-adjacent electrodes with less amplitude with respect to the electrode closest to the foci, and perhaps in synaptically-linked regions such as the contralateral hemisphere^{24,52}. The electric field will not be visible in current aEEG devices because it has only two independent (not chained) bipolar EEG channels, and the spread of the seizure will be evidenced only in the case of propagation to the contralateral hemisphere, where it will be recorded by the other (contralateral) EEG channel. However, the observation of the evolving pattern is sufficient to ensure the diagnosis of epileptic seizures in most cases.

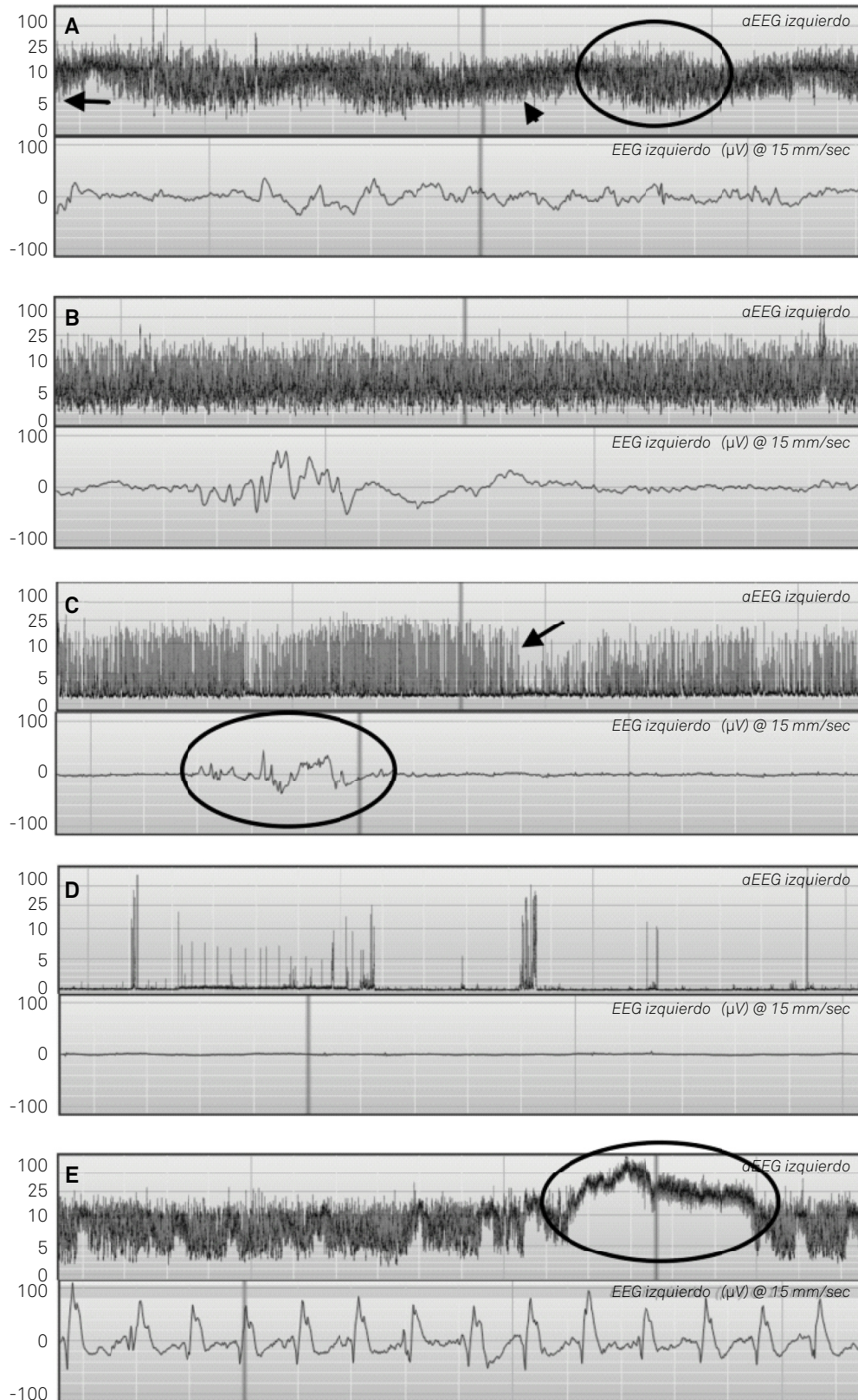


Figure 1. (A) Continuous background pattern, with prominent sleep-wake cycle: upper-margin voltage is > 10 mV and lower margin voltage is > 5 mV (arrow). The sleep-wake cycle is characterized by smooth cyclic variations, mainly of minimum amplitude, with periods of broader bandwidth that represent quiet sleep (circle) and periods of narrow bandwidth that correspond to wakefulness or active sleep (arrowhead). (B) Discontinuous background pattern: upper margin is > 10 mV and lower margin is < 5 mV. The sleep-wake cycle is not present. (C) Burst suppression pattern: upper and lower margin voltages are < 10 mV and < 5 mV respectively reflecting voltage suppression, vertical lines (arrow) show periods of burst. Conventional EEG row shows a brief burst of cerebral activity (circle) between periods of voltage suppression. (D) Isoelectric or flat tracing: both margins are < 5 mV and prominent spikes are likely due to patient movement. (E) Ictal pattern: seizures are shown as a sudden rise in lower and upper margin (circle).

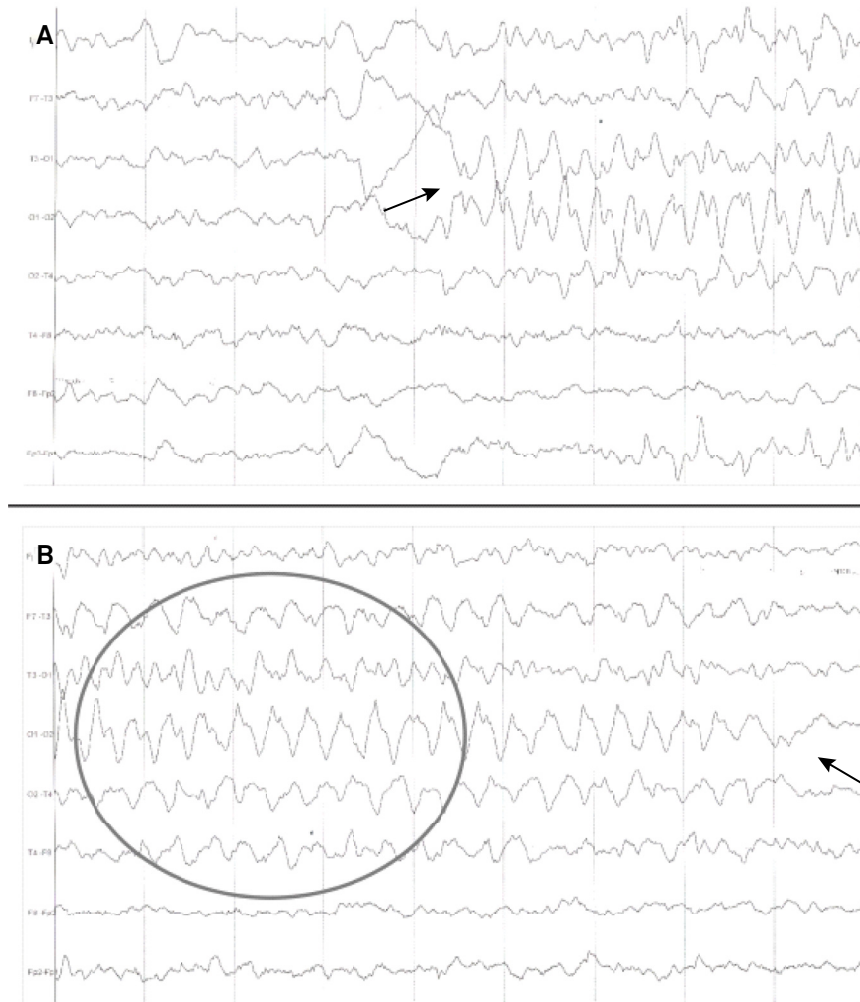


Figure 2. Conventional EEG of a newborn with an electrographic seizure. The beginning of a rhythmic repetitive activity in left occipital area (O1) is marked with the arrow in Figure 2A. The rhythmic discharge evolves in morphology, amplitude and frequency (A and B). Figure 2B shows diffusion to surrounding areas (circle) and the end of the seizure (arrow).

The role of aEEG in the neonatal intensive care unit

The rationale for detecting electrographic seizures rests on the assumption that detection and treatment will ultimately lead to improvement. It is currently unknown whether electrographic seizures independently damage the brain or whether they are mere biomarkers of an underlying brain injury, but evidence from animal studies suggests that seizures may alter brain development and lead to long-term deficits in learning, memory, and behavior^{53,54}. A growing body of literature demonstrates that the electrographic seizure burden is independently associated with worse outcomes, and suggests that electrographic seizures independently contribute to brain damage^{54,55}. It is well known that a significant association exists between seizure duration and severity of brain injury found on cerebral magnetic resonance images in newborns with hypoxic-ischemic encephalopathy⁵⁵.

If we assume that electrographic seizures are damaging the brain and anti-epileptic drugs stop seizures and

improve outcomes, then real-time electrographic seizure detection is critical.

The aEEG performance depends on the degree of expertise and familiarity with aEEG reading, but is easier than conventional EEG and allows bedside seizure detection by practitioners with limited training in neurophysiology. This feature makes it the ideal resource for continuous monitoring within the NICU, even above the gold-standard conventional video EEG, which requires highly-specialized personnel, such that it is impractical for continuous monitoring in real time.

More studies are needed comparing both techniques (conventional EEG versus aEEG), strengths and weaknesses, reliability and reproducibility of the aEEG for the diagnosis of neonatal seizures, as well as the improvement of outcome of newborns with the use of aEEG to determine the real impact of its use in the NICU. But there is no doubt that those who use aEEG should know the basic principles of the electrophysiological diagnosis of seizures to optimize the correct diagnosis of these with aEEG.

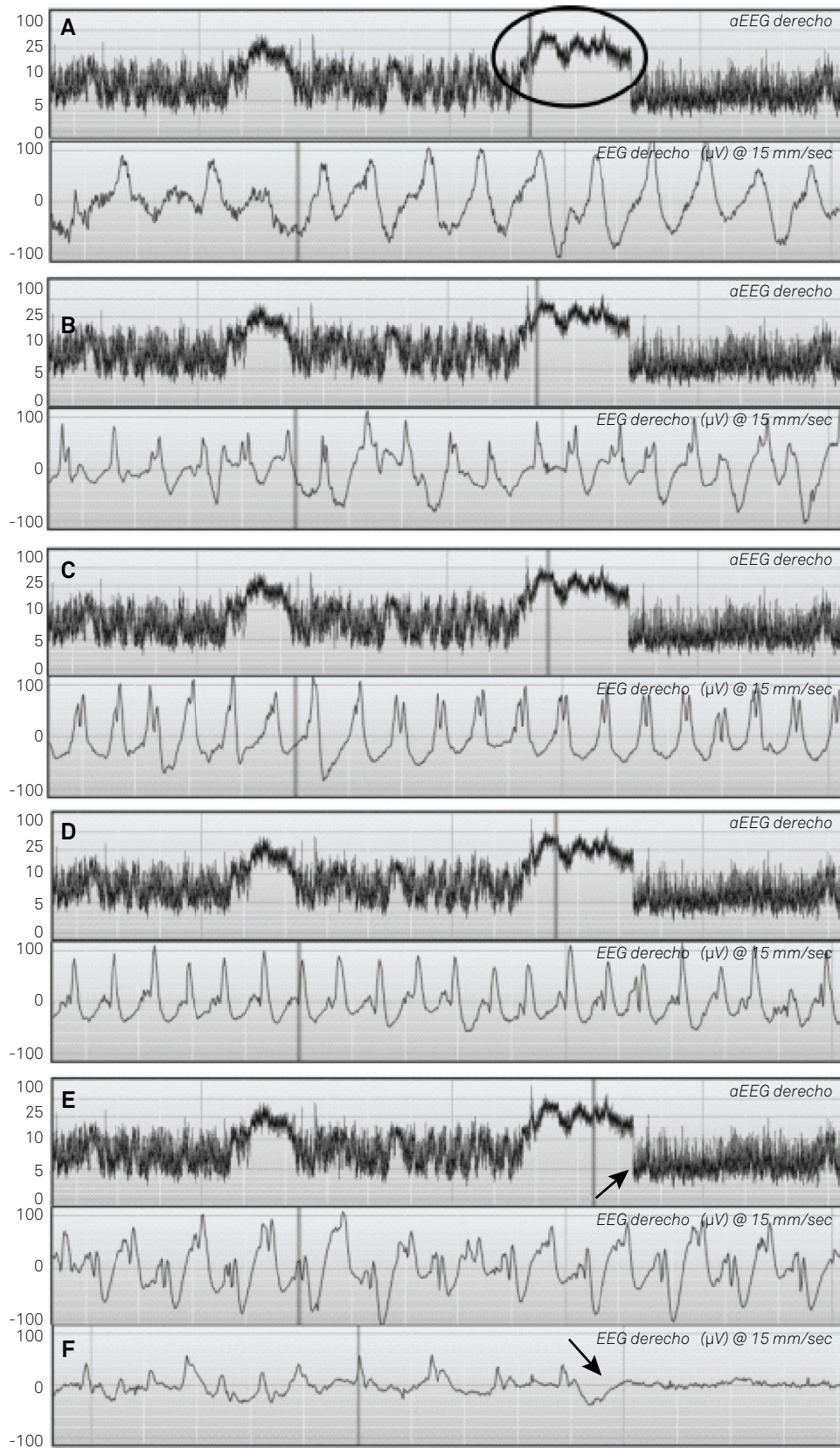


Figure 3. A suspected seizure in the aEEG (circle in A) is reviewed. Each figure (A-E) shows three hours of aEEG trace in the upper row and the corresponding 15 seconds of conventional EEG in the lower row, both traces available simultaneously in current devices. The vertical line in the aEEG shows the part of the trace displayed in the conventional EEG. A repetitive high amplitude slow wave with a rhythmic pattern is noted in the beginning of the seizure (A). In B, C, D and E the ictal pattern evolves progressively in morphology, frequency and amplitude. F shows the end of the seizure (marked with the arrow in E). The spikes are of lower amplitude and lower frequency and at the end of the seizure, voltage flattening is observed (arrow). This figure shows the epileptic seizure typically evolving in frequency, amplitude and morphology.

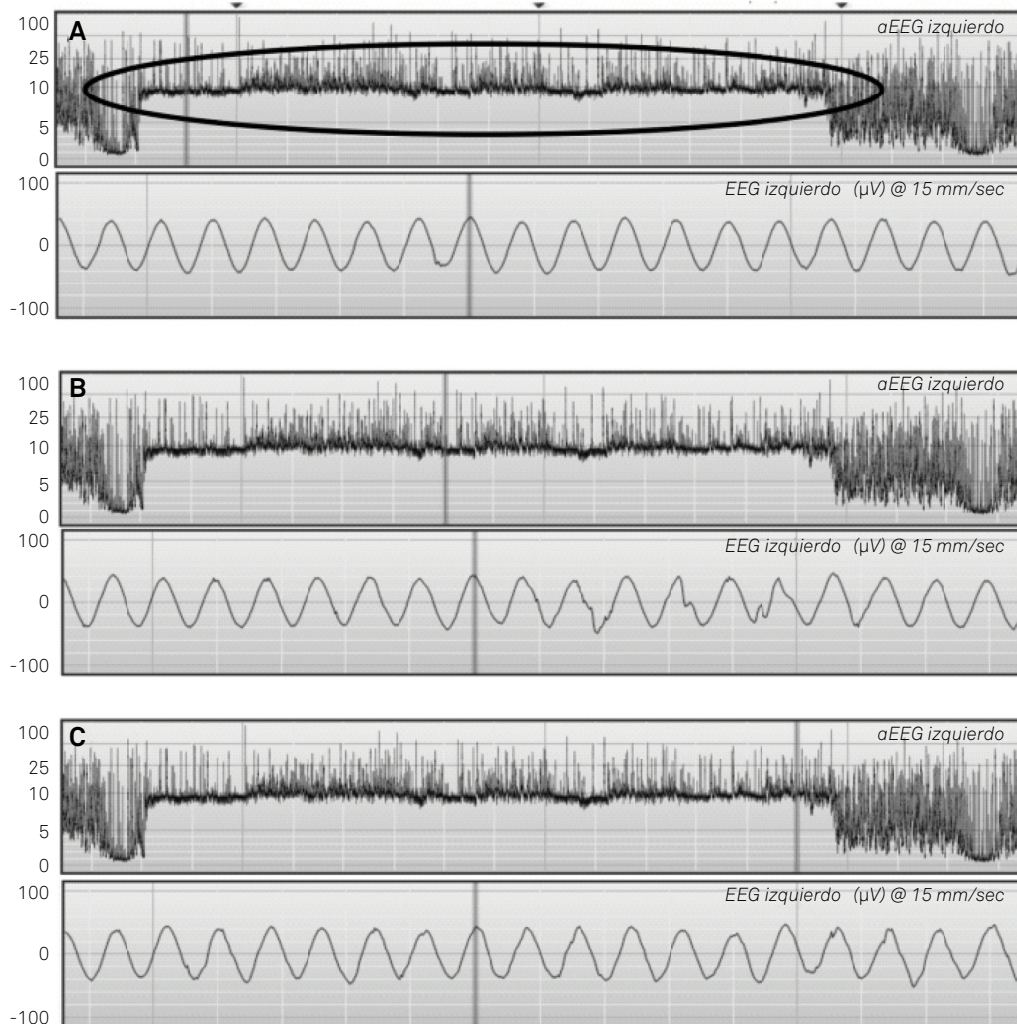


Figure 4. Each figure shows three hours of aEEG (upper row) with the corresponding 15 seconds of conventional EEG in the lower row (arrowhead A marks one hour of trace). The vertical line in the aEEG shows the portion of the trace displayed in the conventional EEG. A sudden rise in lower margin is noted and reviewed (circle in A). In the conventional EEG, the pattern is monorhythmic all along the suspected ictal trace with the same frequency, amplitude and morphology at the beginning (A); 60 minutes later (B); and 120 minutes later at the end of the event (C) refuting the ictal origin of the event.

BEST PRACTICE IN NEONATAL SEIZURE DETECTION WITH THE USE OF AEEG

For correct interpretation, the whole seizure observed in the aEEG trace must be reviewed in the conventional EEG row to confirm the evolving pattern (Figure 3). Most rhythmic artifacts do not show the typical evolving pattern and are thus easily identifiable in the conventional EEG but easily mistaken in the aEEG (Figure 4). Therefore, while the aEEG is useful to quickly visualize the possible ictal episode; concurrent use of the conventional EEG will allow confirmation of the epileptic or nonepileptic origin of the event.

Reviewing the conventional EEG row for each critical episode observed in the aEEG trace optimizes our recognition of seizures such that we can avoid misdiagnosis of artifacts and erroneous treatment of the nonepileptic neonate with anti-epileptic drugs that may have neurotoxic effects⁵⁶.

CONCLUSION

The main value of aEEG is that it permits real-time recognition of electrographic seizures without the need for interpretation by specialized providers.

The hallmark of an electrographic seizure is the sudden appearance of repetitive discharge events consisting of a definite beginning, middle and end, that evolve in frequency, morphological appearance, and amplitude. Rhythmic extracerebral artifacts are typically monomorphic and do not evolve in frequency, morphological appearance, or amplitude.

For proper interpretation of the aEEG, and to avoid misdiagnosing an artifact as a seizure, it is necessary to recognize the ictal pattern in the conventional EEG tracing.

Acknowledgment

The author thanks Brandi Campbell Villa, PhD; Georgia State University, Atlanta, GA, USA, for her assistance in the correction of the text.

References

1. Nardou R, Ferrari DC, Ben-Ari Y. Mechanisms and effects of seizures in the immature brain. *Semin Fetal Neonatal Med.* 2013 Aug;18(4):175-84. <https://doi.org/10.1016/j.siny.2013.02.003>
2. Glass HC, Glidden D, Jeremy RJ, Barkovich AJ, Ferriero DM, Miller SP. Clinical neonatal seizures are independently associated with outcome in infants at risk for hypoxic-ischemic brain injury. *J Pediatr.* 2009 Sep;155(3):318-23. <https://doi.org/10.1016/j.jpeds.2009.03.040>
3. Nagarajan L, Palumbo L, Ghosh S. Neurodevelopmental outcomes in neonates with seizures: a numerical score of background electroencephalography to help prognosticate. *J Child Neurol.* 2010 Aug;25(8):961-8. <https://doi.org/10.1177/0883073809355825>
4. Clancy RR, Legido A, Lewis D. Occult neonatal seizures. *Epilepsia.* 1988 May-Jun;29(3):256-61. <https://doi.org/10.1111/j.1528-1157.1988.tb03715.x>
5. Rosén I. The physiological basis for continuous electroencephalogram monitoring in the neonate. *Clin Perinatol.* 2006 Sep;33(3):593-611. <https://doi.org/10.1016/j.clp.2006.06.013>
6. Connell JA, Oozer R, Dubowitz V. Continuous 4-channel EEG monitoring: a guide to interpretation, with normal values, in preterm infants. *Neuropediatrics.* 1987 Aug;18(3):138-45. <https://doi.org/10.1055/s-2008-1052466>
7. Lamblin MD, André M, Challamel MJ, Curzi-Dascalova L, d'Allest AM, De Giovanni E et al. [Electroencephalography of the premature and term newborn. Maturation aspects and glossary]. *Neurophysiol Clin.* 1999 Apr;29(2):123-219. French. [https://doi.org/10.1016/S0987-7053\(99\)80051-3](https://doi.org/10.1016/S0987-7053(99)80051-3)
8. Holmes GL, Lombroso CT. Prognostic value of background patterns in the neonatal EEG. *J Clin Neurophysiol.* 1993 Jul;10(3):323-52. <https://doi.org/10.1097/00004691-199307000-00008>
9. Nanavati T, Seemaladinne N, Regier M, Yossuck P, Pergami P. Can we predict functional outcome in neonates with hypoxic ischemic encephalopathy by the combination of neuroimaging and electroencephalography? *Pediatr Neonatol.* 2015 Oct;56(5):307-16. <https://doi.org/10.1016/j.pedneo.2014.12.005>
10. Clancy RR, Bergqvist AG, Dulgos DJ. Neonatal electroencephalography. In: Ebersole JS, Pedley TA, editors. *Current practice of clinical electroencephalography.* 3rd ed. Philadelphia: Lippincott Williams & Wilkins; 2003. pp. 160-234.
11. Rakshashbuvankar A, Paul S, Nagarajan L, Ghosh S, Rao S. Amplitude-integrated EEG for detection of neonatal seizures: a systematic review. *Seizure.* 2015 Dec;33:90-8. <https://doi.org/10.1016/j.seizure.2015.09.014>
12. Toet MC, Meij W, Vries LS, Uiterwaal CS, Huffelen KC. Comparison between simultaneously recorded amplitude integrated electroencephalogram (cerebral function monitor) and standard electroencephalogram in neonates. *Pediatrics.* 2002 May;109(5):772-9. <https://doi.org/10.1542/peds.109.5.772>
13. Rennie JM, Chorley G, Boylan GB, Pressler R, Nguyen Y, Hooper R. Non-expert use of the cerebral function monitor for neonatal detection of neonatal seizures detection. *Arch Dis Child Fetal Neonatal Ed.* 2004;89(1):37-40. <https://doi.org/10.1136/fn.89.1.F37>
14. Shellhaas RA, Soaita AI, Clancy RR. Sensitivity of amplitude-integrated electroencephalography for neonatal neonatal seizures detection. *Pediatrics.* 2007;120(4):770-7. <https://doi.org/10.1542/peds.2007-0514>
15. Shah DK, Mackay MT, Lavery S, Watson S, Harvey AS, Zempel J et al. Accuracy of bedside electroencephalographic monitoring in comparison with simultaneous continuous conventional electroencephalography for seizure detection in term infants. *Pediatrics.* 2008;121(6):1146-54. <https://doi.org/10.1542/peds.2007-1839>
16. Lawrence R, Mathur A, Nguyen The Tich S, Zempel J, Inder T. A pilot study of continuous limited-channel aEEG in term infants with encephalopathy. *J Pediatr.* 2009 Jun;154(6):835-41.e1. <https://doi.org/10.1016/j.jpeds.2009.01.002>
17. Bourez-Swart MD, van Rooij L, Rizzo C, de Vries LS, Toet MC, Gebbink TA et al. Detection of subclinical electroencephalographic seizure patterns with multichannel amplitude-integrated EEG in full-term neonates. *Clin Neurophysiol.* 2009 Nov;120(11):1916-22. <https://doi.org/10.1016/j.clinph.2009.08.015>
18. Evans E, Koh S, Lerner J, Sankar R, Garg M. Accuracy of amplitude integrated EEG in a neonatal cohort. *Arch Dis Child Fetal Neonatal Ed.* 2010 May;95(3):F169-73. <https://doi.org/10.1136/adc.2009.165969>
19. Frenkel N, Friger M, Meledin I, Berger I, Marks K, Bassan H et al. Neonatal seizure recognition—comparative study of continuous-amplitude integrated EEG versus short conventional EEG recordings. *Clin Neurophysiol.* 2011 Jun;122(6):1091-7. <https://doi.org/10.1016/j.clinph.2010.09.028>
20. Zhang L, Zhou YX, Chang LW, Luo XP. Diagnostic value of amplitude-integrated electroencephalogram in neonatal seizures. *Neurosci Bull.* 2011 Aug;27(4):251-7. <https://doi.org/10.1007/s12264-011-1413-x>
21. Mastrangelo M, Fiocchi I, Fontana P, Gorgone G, Lista G, Belcastro V. Acute neonatal encephalopathy and seizures recurrence: a combined aEEG/EEG study. *Seizure.* 2013 Nov;22(9):703-7. <https://doi.org/10.1016/j.seizure.2013.05.006>
22. Jan S, Northington FJ, Parkinson CM, Stafstrom CE. EEG Monitoring technique influences the management of hypoxic-ischemic seizures in neonates undergoing therapeutic hypothermia. *Dev Neurosci.* 2017;39(1-4):82-8. <https://doi.org/10.1159/000454855>
23. Rakshashbuvankar A, Rao S, Palumbo L, Ghosh S, Nagarajan L. Amplitude integrated electroencephalography compared with conventional video EEG for neonatal seizure detection: a diagnostic accuracy study. *J Child Neurol.* 2017 Aug;32(9):815-22. <https://doi.org/10.1177/0883073817707411>
24. Patrizi S, Holmes GL, Orzalesi M, Allemand F. Neonatal seizures: characteristics of EEG ictal activity in preterm and fullterm infants. *Brain Dev.* 2003 Sep;25(6):427-37. [https://doi.org/10.1016/S0387-7604\(03\)00031-7](https://doi.org/10.1016/S0387-7604(03)00031-7)
25. Mizrahi EM, Kellaway P. *Diagnosis and management of neonatal seizures.* Philadelphia: Lippincott-Raven; 1998.
26. Pinto LC, Giliberti P. Neonatal seizures: background EEG activity and the electroclinical correlation in full-term neonates with hypoxic-ischemic encephalopathy. Analysis by computer-synchronized long-term polygraphic video-EEG monitoring. *Epileptic Disord.* 2001 Sep;3(3):125-32.
27. Olson DM. Neonatal Seizures. *Neoreviews.* 2012 Apr;13(4):e213. <https://doi.org/10.1542/neo.13-4-e213>
28. Glass HC, Wirrell E. Controversies in neonatal seizure management. *J Child Neurol.* 2009 May;24(5):591-9. <https://doi.org/10.1177/0883073808327832>
29. Vesoulis ZA, Mathur AM. Advances in management of neonatal seizures. *Indian J Pediatr.* 2014 Jun;81(6):592-8. <https://doi.org/10.1007/s12098-014-1457-9>
30. Watanabe K. Neurophysiological aspects of neonatal seizures. *Brain Dev.* 2014 May;36(5):363-71. <https://doi.org/10.1016/j.braindev.2014.01.016>
31. Volpe JJ. Neonatal seizures: current concepts and revised classification. *Pediatrics.* 1989 Sep;84(3):422-8.
32. Mizrahi EM, Kellaway P. Characterization and classification of neonatal seizures. *Neurology.* 1987 Dec;37(12):1837-44. <https://doi.org/10.1212/WNL.37.12.1837>

33. Hellström-Westas L, Rosén I, Swenningsen NW. Silent seizures in sick infants in early life. Diagnosis by continuous cerebral function monitoring. *Acta Paediatr Scand*. 1985 Sep;74(5):741-8. <https://doi.org/10.1111/j.1651-2227.1985.tb10024.x>
34. Murray DM, Boylan GB, Ali I, Ryan CA, Murphy BP, Connolly S. Defining the gap between electrographic seizure burden, clinical expression and staff recognition of neonatal seizures. *Arch Dis Child Fetal Neonatal Ed*. 2008 May;93(3):F187-91. <https://doi.org/10.1136/adc.2005.086314>
35. Mizrahi EM, Harchovoy RA. Atlas of neonatal electroencephalography. 4th ed. New York: Demos Medical Publishing; 2016. pp. 239-93.
36. Maynard D, Prior PF, Scott DF. Device for continuous monitoring of cerebral activity in resuscitated patients. *BMJ*. 1969 Nov;4(5682):545-6. <https://doi.org/10.1136/bmj.4.5682.545-a>
37. Viniker DA, Maynard DE, Scott DF. Cerebral function monitor studies in neonates. *Clin Electroencephalogr*. 1984 Oct;15(4):185-92. <https://doi.org/10.1177/155005948401500401>
38. Tao JD, Mathur AM. Using amplitude-integrated EEG in neonatal intensive care. *J Perinatol*. 2010 Oct;30 Suppl:S73-81. <https://doi.org/10.1038/jp.2010.93>
39. Del Río R, Ochoa C, Alarcon A, Arnáez J, Blanco D, García-Alix A. Amplitude integrated electroencephalogram as a prognostic tool in neonates with hypoxic-ischemic encephalopathy: a systematic review. *PLoS One*. 2016 Nov;11(11):e0165744. <https://doi.org/10.1371/journal.pone.0165744>
40. Ancora G, Maranella E, Grandi S, Sbravati F, Coccolini E, Savini S et al. Early predictors of short term neurodevelopmental outcome in asphyxiated cooled infants. A combined brain amplitude integrated electroencephalography and near infrared spectroscopy study. *Brain Dev*. 2013 Jan;35(1):26-31. <https://doi.org/10.1016/j.braindev.2011.09.008>
41. Shankaran S, Pappas A, McDonald SA, Laptook AR, Bara R, Ehrenkranz RA et al.; Eunice Kennedy Shriver National Institute of Child Health and Human Development Neonatal Research Network. Predictive value of an early amplitude integrated electroencephalogram and neurologic examination. *Pediatrics*. 2011 Jul;128(1):e112-20. <https://doi.org/10.1542/peds.2010-2036>
42. Gucuyener K, Beken S, Ergenekon E, Soysal S, Hirfanoglu I, Turan O et al. Use of amplitude-integrated electroencephalography (aEEG) and near infrared spectroscopy findings in neonates with asphyxia during selective head cooling. *Brain Dev*. 2012 Apr;34(4):280-6. <https://doi.org/10.1016/j.braindev.2011.06.005>
43. Csekő AJ, Bangó M, Lakatos P, Kárdási J, Pusztai L, Szabó M. Accuracy of amplitude-integrated electroencephalography in the prediction of neurodevelopmental outcome in asphyxiated infants receiving hypothermia treatment. *Acta Paediatr*. 2013 Jul;102(7):707-11. <https://doi.org/10.1111/apa.12226>
44. Azzopardi D; TOBY study group. Predictive value of the amplitude integrated EEG in infants with hypoxic ischaemic encephalopathy: data from a randomised trial of therapeutic hypothermia. *Arch Dis Child Fetal Neonatal Ed*. 2014 Jan;99(1):F80-2. <https://doi.org/10.1136/archdischild-2013-303710>
45. Dunne JM, Wertheim D, Clarke P, Kapellou O, Chisholm P, Boardman JP et al. Automated electroencephalographic discontinuity in cooled newborns predicts cerebral MRI and neurodevelopmental outcome. *Arch Dis Child Fetal Neonatal Ed*. 2017 Jan;102(1):F58-64. <https://doi.org/10.1136/archdischild-2015-309697>
46. Bye AM, Flanagan D. Spatial and temporal characteristics of neonatal seizures. *Epilepsia*. 1995 Oct;36(10):1009-16. <https://doi.org/10.1111/j.1528-1157.1995.tb00960.x>
47. de Vries LS, Hellström-Westas L. Role of cerebral function monitoring in the newborn. *Arch Dis Child Fetal Neonatal Ed*. 2005 May;90(3):F201-7. <https://doi.org/10.1136/adc.2004.062745>
48. Moshé SL. Epileptogenesis and the immature brain. *Epilepsia*. 1987;28(s1 Suppl 1):S3-15. <https://doi.org/10.1111/j.1528-1157.1987.tb05753.x>
49. Spinosa MJ, Liberalesso PBN, Mehl L, Löhr Junior A. Ictal pattern in children: an illustrated review. *J Epilepsy Clin Neurophysiol*. 2011;17(4):154-63. <https://doi.org/10.1590/S1676-26492011000400008>
50. Kane N, Acharya J, Benickzy S, Caboclo L, Finnigan S, Kaplan PW et al. A revised glossary of terms most commonly used by clinical electroencephalographers and updated proposal for the report format of the EEG findings. Revision 2017. *Clin Neurophysiol Pract*. 2017 Aug;2:170-85. <https://doi.org/10.1016/j.cnp.2017.07.002>
51. Niemarkt H, Andriessen P, Halbertsma FJ. Artefacts in the amplitude-integrated EEG background pattern of a full-term asphyxiated neonate caused by diaphragm spasms. *BMJ Case Rep*. 2012 May;2012(may29 1):2012. <https://doi.org/10.1136/bcr.12.2011.5363>
52. Fisher RS, Scharfman HE, deCurtis M. How can we identify ictal and interictal abnormal activity? *Adv Exp Med Biol*. 2014;813:3-23. https://doi.org/10.1007/978-94-017-8914-1_1
53. Gibbs SA, Scantlebury MH, Awad P, Lema P, Essouma JB, Parent M et al. Hippocampal atrophy and abnormal brain development following a prolonged hyperthermic seizure in the immature rat with a focal neocortical lesion. *Neurobiol Dis*. 2008 Oct;32(1):176-82. <https://doi.org/10.1016/j.nbd.2008.07.005>
54. Holmes GL. The long-term effects of neonatal seizures. *Clin Perinatol*. 2009 Dec;36(4):901-14. <https://doi.org/10.1016/j.clp.2009.07.012>
55. Rooij LG, Toet MC, Huffelen AC, Groenendaal F, Laan W, Zecic A et al. Effect of treatment of subclinical neonatal seizures detected with aEEG: randomized, controlled trial. *Pediatrics*. 2010 Feb;125(2):e358-66. <https://doi.org/10.1542/peds.2009-0136>
56. Bittigau P, Sifringer M, Genz K, Reith E, Pospischil D, Govindarajulu S et al. Antiepileptic drugs and apoptotic neurodegeneration in the developing brain. *Proc Natl Acad Sci USA*. 2002 Nov;99(23):15089-94. <https://doi.org/10.1073/pnas.222550499>